



CHAPTER

8

Wide Local Excision

CRITICAL ELEMENTS

- Margin Width
- Depth of Excision
- Anatomic Orientation of the Excision

1. MARGIN WIDTH

Recommendation: The margin width for wide local excision of melanoma is based on the Breslow thickness of the primary tumor. Margin width should be 1 cm for melanomas <1 mm thick, 1 or 2 cm for melanomas 1 to 2 mm thick, and 2 cm for melanomas >2 mm thick. The margin width for wide local excision of a melanoma in situ should be 5 mm. Standard wide local excision margin recommendations also apply to melanomas of the skin of the digits. Subungual melanoma frequently requires amputation of a distal phalanx.

Type of Data: Melanoma randomized controlled trials; observational studies in subungual melanoma in situ.

Grade of Recommendation: Strong recommendation, high-quality evidence; subungual melanoma: weak recommendation, high-quality evidence.

Rationale

The purpose of melanoma wide local excision (WLE) is to obtain local control by removing the primary tumor as well as the local at-risk subcutaneous lymphatics. The margin is measured circumferentially at the level of the skin from either residual gross tumor and/or the previous biopsy scar.

The recommended WLE margin for melanoma in situ (MIS), according to a 1992 National Institutes of Health consensus panel, is 5 mm (Table 8-1).¹ This measure is not based on randomized trial results or any prospective data. In some particular MIS

390

TABLE 8-1 Recommended Wide Local Excision Margins for Primary Melanoma Based on Breslow Thickness

Thickness of Melanoma (mm)	Measured Surgical Margin Width (cm)	Strength of Recommendation	Evidence
Melanoma in situ	0.5	Weak	Consensus
<1.0	1	Strong	RCT
1.0–2.0	1 or 2	Strong	RCT
>2.0	2	Strong	RCT

RCT, randomized controlled trial.

subtypes, such as lentigo maligna melanoma, that may have subclinical extension, 1-cm margins may be needed to obtain negative margins.²

For melanomas <1.0 mm thick, the recommended WLE margin is 1 cm. For melanomas 1 to 2 mm thick, the recommended margin width is 1 or 2 cm. This recommendation is based on results from a World Health Organization RCT, where patients with melanomas up to 2 mm thick were randomly assigned to WLE with 1- or 3-cm margins.^{3,4} At follow-up 10 years later, local recurrence rates and survival were comparable between the two groups. RCTs conducted by the Swedish Melanoma Study Group and French Cooperative Group compared margins of 2 cm and 5 cm and found no significant difference in either local recurrence or overall survival.^{5,6}

Given that there are no strong data to favor 1-cm over 2-cm WLE margins for melanomas 1 to 2 mm thick, the decision regarding margin width should include other clinical factors, such as the melanoma's anatomic location and the possibility of performing a primary closure (rather than resorting to skin grafting or a complex flap closure). The ability to use clinical discretion is supported by consensus statements, including one from the National Comprehensive Cancer Network.⁷ At anatomic locations such as the head and neck or the plantar foot, where wider margins may be unachievable or highly disfiguring, a 1-cm margin would be acceptable on an individualized basis. When the anatomic location does not present a specific concern, a 2-cm margin can be considered.

Although no prospective randomized trials have examined a 1-cm versus 2-cm margin specifically for melanoma 1 to 2 mm thick, there is a retrospective single-institution study of 965 such patients whose procedures included a WLE with a 1-cm ($n = 302$ [31.3%]) or 2-cm ($n = 663$ [68.7%]) margin.⁸ Thirty-three percent of patients with head and neck melanoma and 49% of patients with melanoma on an extremity had a WLE with a 1-cm margin, whereas only 19% of patients with truncal melanoma had a WLE with a 1-cm margin. Local recurrence and 5-year disease-specific survival were no different between the group with 1-cm margins and the group with 2-cm margins. Additionally, a 2-cm margin at the head and neck location was associated with an increased need for either a skin graft or flap reconstruction.

For melanomas 2 to 4 mm thick, several randomized trials have shown that a 2-cm WLE margin is adequate. The Melanoma Intergroup Trial compared 2-cm with

4-cm margins when the melanomas were of intermediate thickness, noting similar local recurrence and survival rates but finding lower complication rates in the group with 2-cm margins.⁹⁻¹¹ A British RCT comparing 1-cm margins with 3-cm margins for primary melanoma >2 mm found a significantly higher local recurrence rate in the group with 1-cm margins, supporting the recommendation for a 2-cm margin.^{12,13} There are no data to support margins of >2 cm for thick primary melanoma (melanomas >4 mm thick).

The appropriate WLE margins are measured from the periphery of any gross residual tumor or the edges of the entire previous biopsy scar (shave or excisional). In certain situations, a Wood's lamp (ultraviolet or black light) can be useful in improving identification of the periphery of an ill-defined, irregular melanoma or MIS. The WLE specimen should always be oriented for pathology in a manner that allows for accurate assessment of specific margins.

Intraoperative evaluation of the WLE margins by frozen section is not routinely performed. Complicating frozen-section margin assessment are tissue folding; freeze artifact; stacking of keratinocytes, melanocytes, or both in thicker tissue sections; and sun damage-related melanocytic hyperplasia. If there is concern about positive margins when WLE is being performed for a large, ill-defined tumor, the surgeon could consider performing a staged procedure of WLE with wound packing followed by definitive closure once the pathologic margin status has been determined on permanent section.

If a primary closure is being performed, the circular or oval-shaped WLE is often converted into a fusiform ellipse (Fig. 8-1). Although traditional teaching holds that the length of the fusiform ellipse should be three to four times the width to minimize skin elevation at the ends of the incision, this rule primarily applies to the extremities where the WLE results in significant changes in limb circumference over a limited area. In contrast, WLE on a flat surface such as the torso can often have a minimal length-to-width ratio and still have a favorable cosmetic appearance.

Standard WLE margin recommendations also apply to melanomas involving the skin of the digits. For melanomas of the web space between the digits, resection and reconstruction can often be performed without requiring amputation.¹⁴

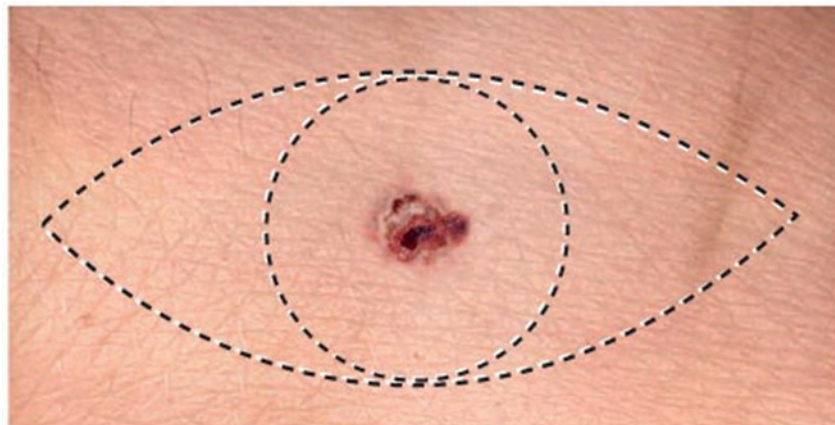


FIGURE 8-1 Creation of a longitudinally oriented fusiform ellipse for melanoma wide excision.

Although oncologic principles do not mandate resection of bone for a subungual melanoma, performing the appropriate WLE typically leaves insufficient soft tissue to support a functional digit. Consequently, subungual melanomas are generally treated with distal phalanx amputation.

2. DEPTH OF EXCISION

Recommendation: For wide local excision of melanoma, all of the skin and underlying subcutaneous tissue should be removed down to the level of the underlying muscular fascial plane to remove the adjacent subcutaneous lymphatics. Given that melanoma in situ is preinvasive, the wide local excision should include only the skin and the superficial subcutaneous fat.

Type of Data: Observational studies.

Grade of Recommendation: Weak recommendation, low-quality evidence.

Rationale

Although prospective randomized trial data exist for the radial margin width for melanoma WLE, there is little prospective data for the depth of the oncologic excision. The consensus is that all of the skin and underlying subcutaneous tissue should be removed down to the level of the underlying muscular fascial plane (Fig. 8-2). Removal of the muscular fascia is not associated with improved locoregional control or survival.¹⁵

This concept of an oncologic removal of the full-thickness skin and subcutaneous tissue down to muscular fascia is applicable to primary tumors on the trunk, extremities, and the scalp. However, there are certain anatomic sites where a different technique needs to be used for the depth of excision. Around the lateral commissure of the mouth, the excision should be taken only into the subcutaneous tissue to preserve the marginal mandibular branch of the facial nerve. For the skin of the female breast, the oncologic resection should include the skin and subcutaneous tissue, but not breast parenchyma. For the ear, the recommended oncologic approach is to perform a full-thickness wedge-type excision or partial amputation, including cartilage.

Given that MIS is preinvasive, there should be no risk of local lymphatic involvement. Therefore, WLE does not need to include the full-thickness subcutaneous tissue to the level of the fascia; a small amount of superficial subcutaneous fat underlying the skin (to ensure complete removal of the dermis) is considered adequate.

3. ANATOMIC ORIENTATION OF THE EXCISION

Recommendation: The axis of orientation for a wide local excision of melanoma on the extremities should generally be axial. A wide local excision on the trunk should be oriented with the lines of Langer.

Type of Data: Observational studies.

Grade of Recommendation: Weak recommendation, low-quality evidence.