



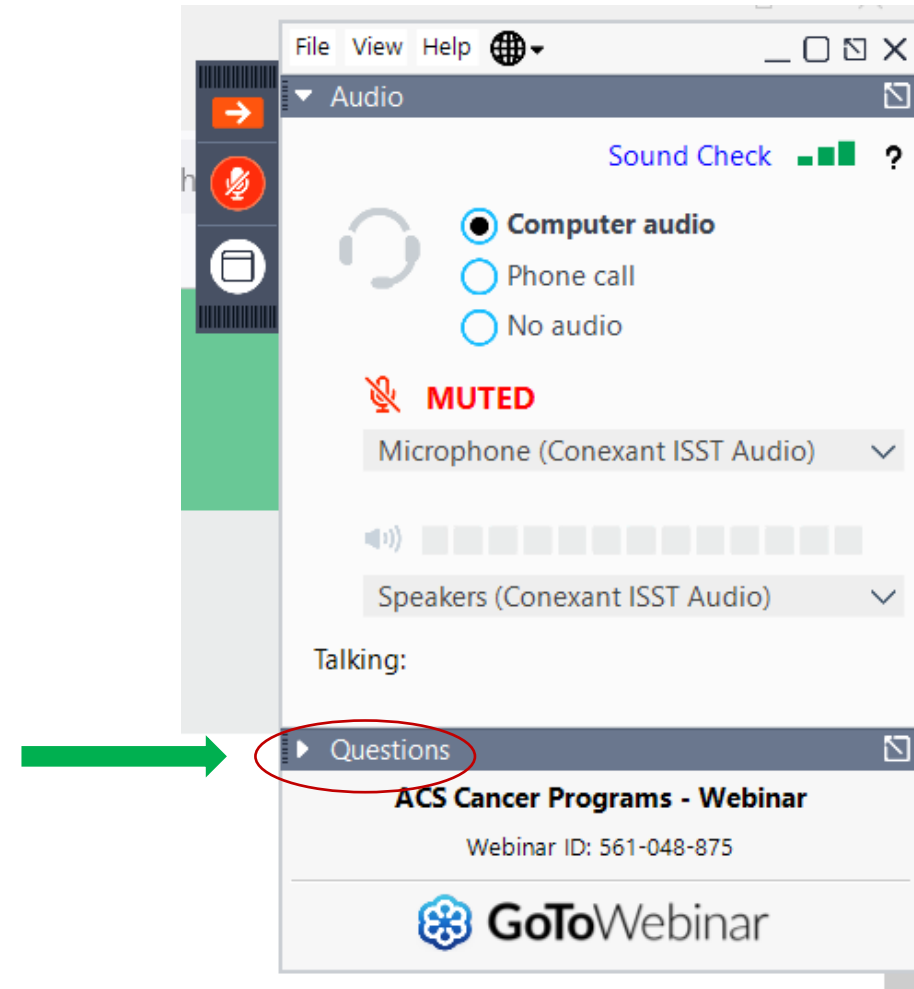
**National Accreditation Program for Rectal Cancer**  
American College of Surgeons

# Standard 5.10 Photographs of Surgical Specimens: Challenges and Solutions with Implementing the Standard

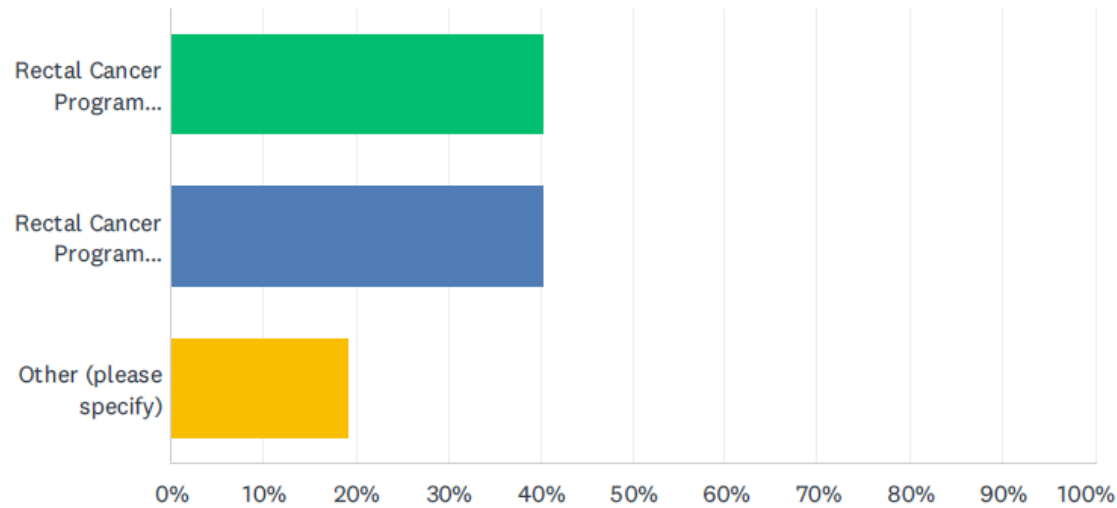
April 18, 2023

# Logistics

- All participants are muted during the webinar
- Questions – including technical issues you may be experiencing – should be submitted through the question pane
- Questions will be answered as time permits; additional questions and answers will be posted on the website
- Please complete the post-webinar evaluation you will receive via email

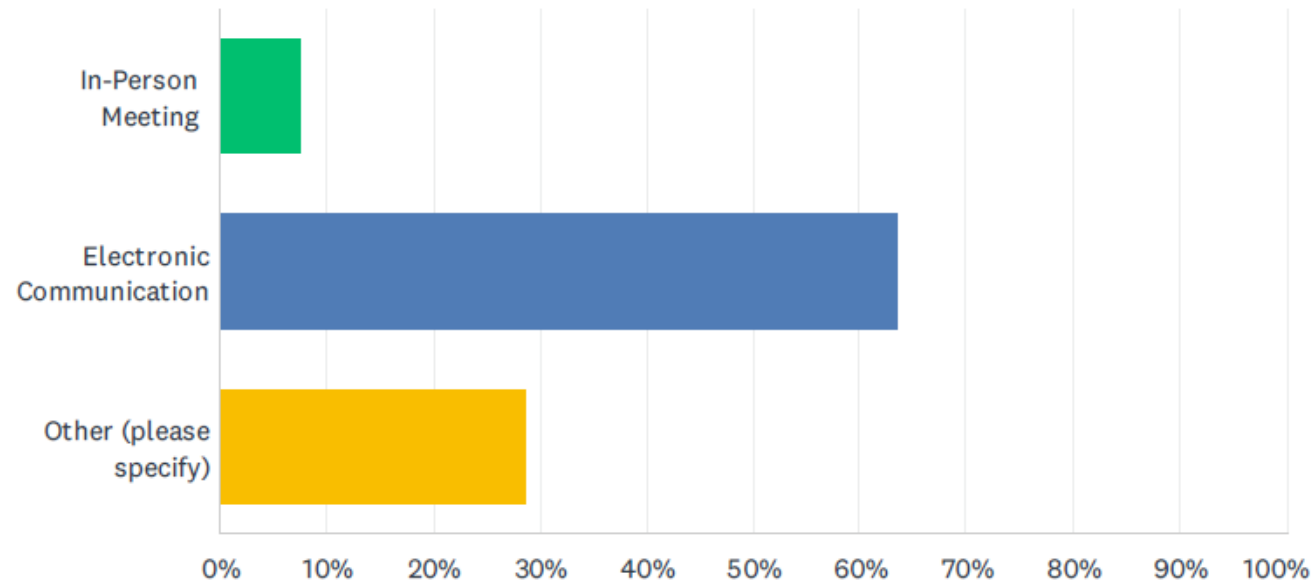


# What is your NAPRC role?



ANSWER CHOICES	RESPONSES	
Rectal Cancer Program Director	40.38%	21
Rectal Cancer Program Coordinator	40.38%	21
Other (please specify)	19.23%	10
<b>TOTAL</b>		<b>52</b>

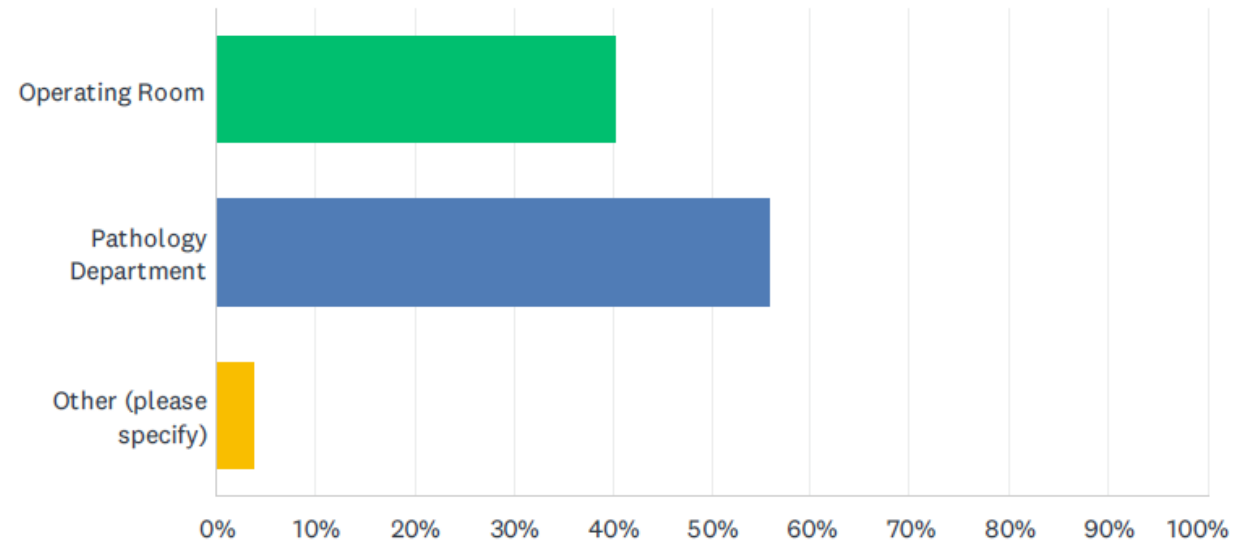
# How do you notify your pathology department of an upcoming case?



ANSWER CHOICES	RESPONSES	
In-Person Meeting	7.69%	4
Electronic Communication	63.46%	33
Other (please specify)	28.85%	15
<b>TOTAL</b>		<b>52</b>

# Where are pictures of rectal cancer specimens being taken?

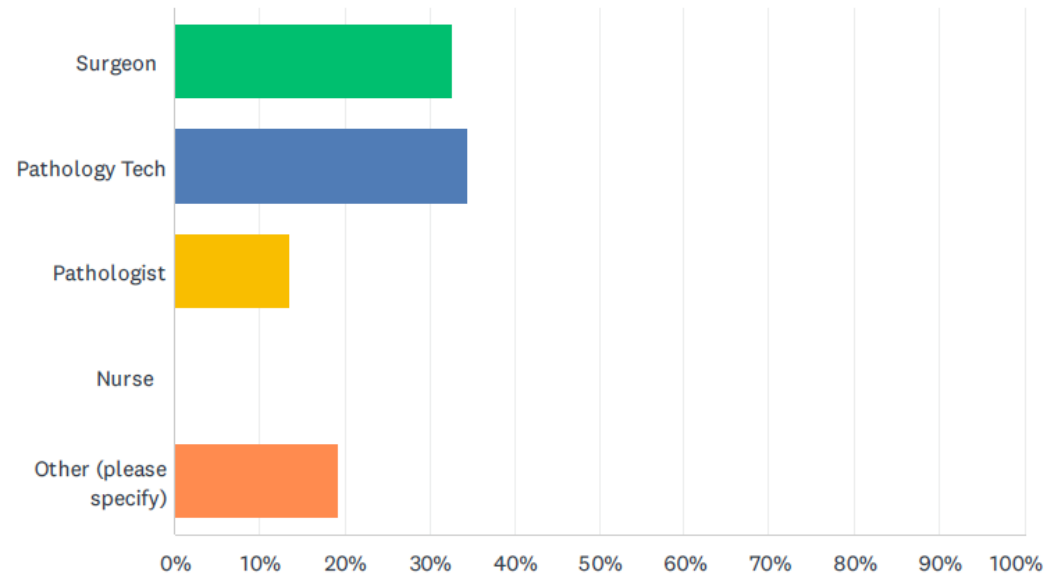
Answered: 52 Skipped: 0



ANSWER CHOICES	RESPONSES	
Operating Room	40.38%	21
Pathology Department	55.77%	29
Other (please specify)	3.85%	2
<b>TOTAL</b>		<b>52</b>

# Who is taking the pictures?

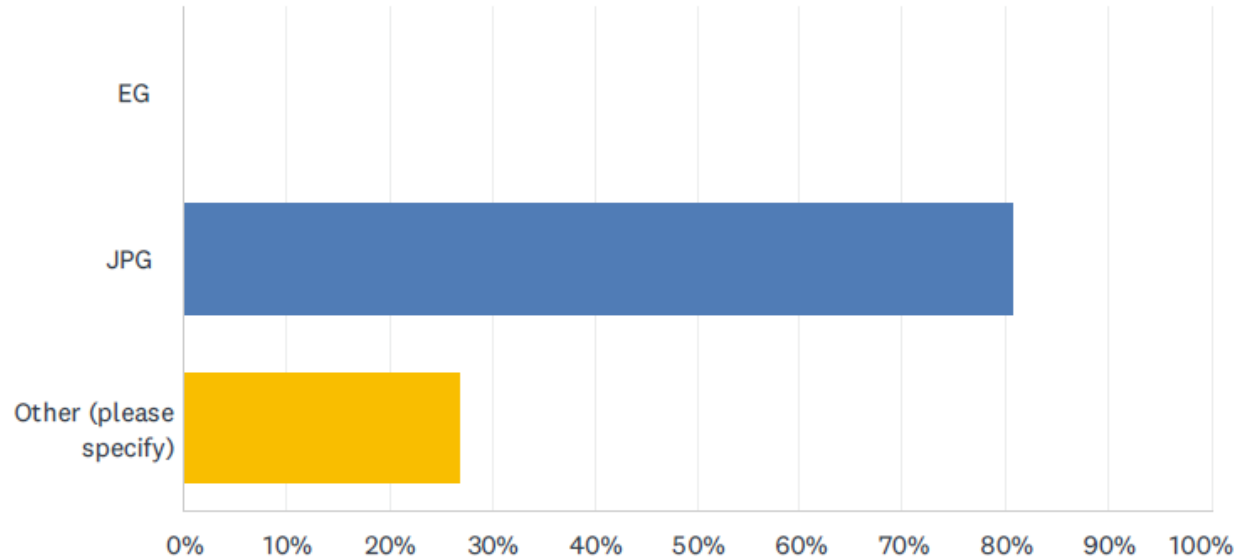
Answered: 52 Skipped: 0



ANSWER CHOICES	RESPONSES	
Surgeon	32.69%	17
Pathology Tech	34.62%	18
Pathologist	13.46%	7
Nurse	0.00%	0
Other (please specify)	19.23%	10
<b>TOTAL</b>		<b>52</b>

# What format are these pictures being stored in?

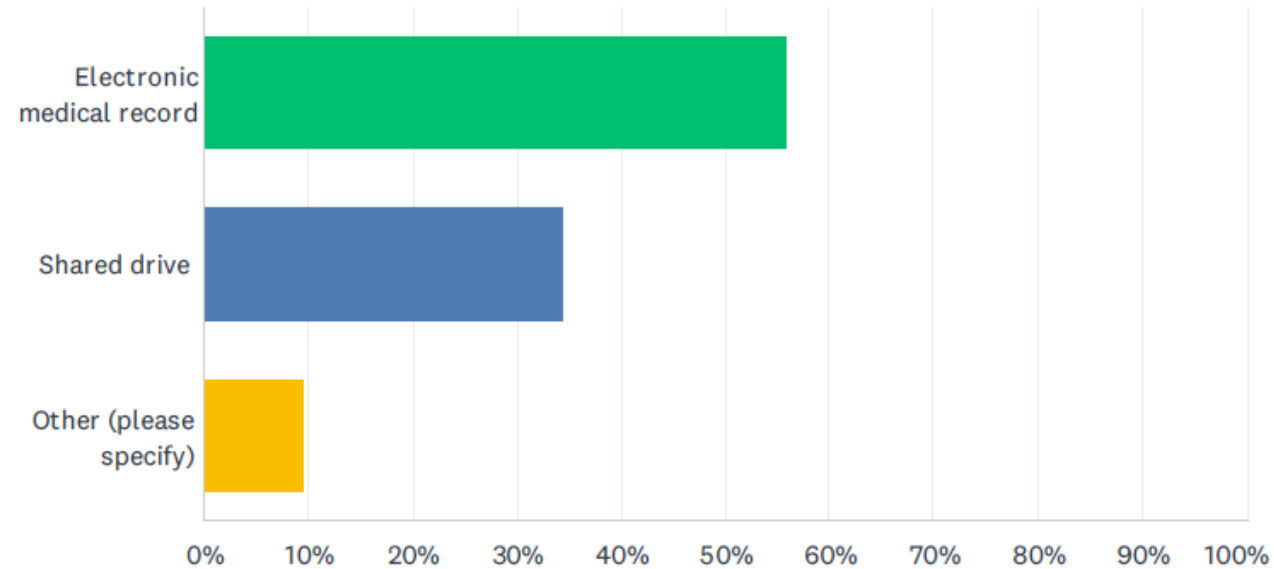
Answered: 52 Skipped: 0



ANSWER CHOICES	RESPONSES	
EG	0.00%	0
JPG	80.77%	42
Other (please specify)	26.92%	14
Total Respondents: 52		

# Where are the photos being uploaded?

Answered: 52 Skipped: 0

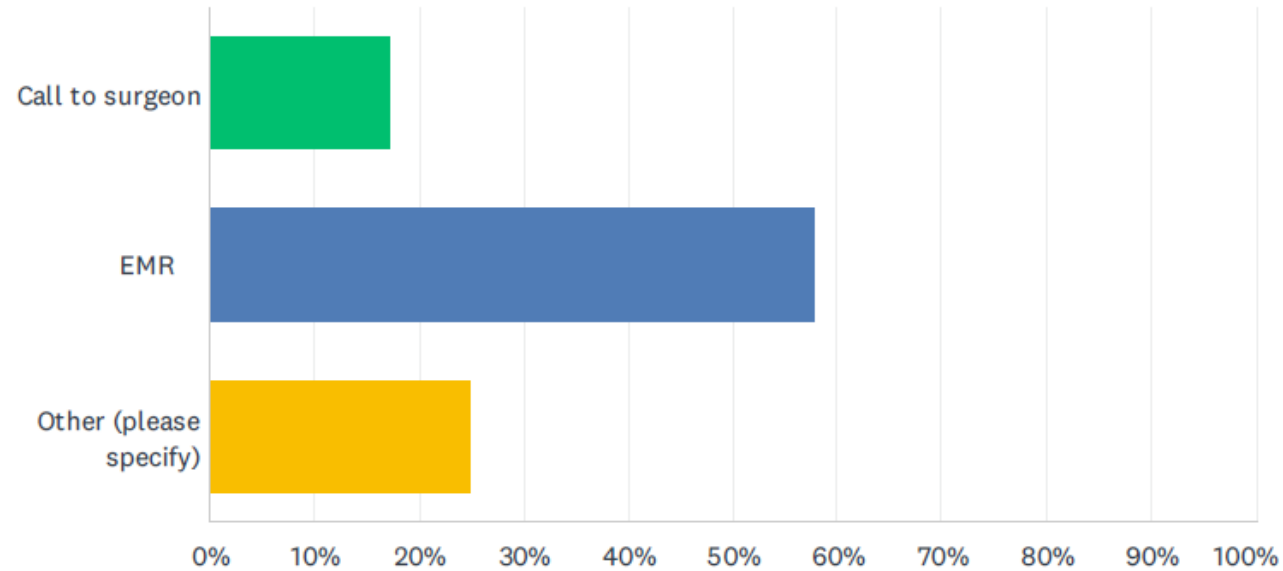


ANSWER CHOICES	RESPONSES	
Electronic medical record	55.77%	29
Shared drive	34.62%	18
Other (please specify)	9.62%	5
<b>TOTAL</b>		<b>52</b>



# How is the mesorectal grade and distal margin conveyed?

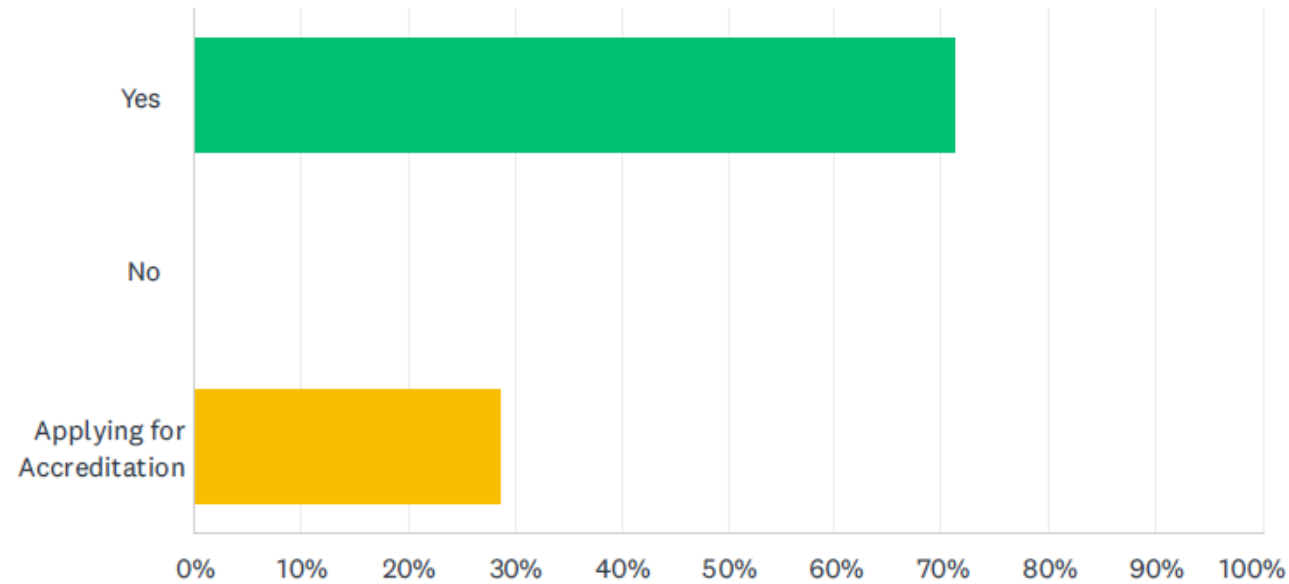
Answered: 52 Skipped: 0



ANSWER CHOICES	RESPONSES	
Call to surgeon	17.31%	9
EMR	57.69%	30
Other (please specify)	25.00%	13
<b>TOTAL</b>		<b>52</b>

# Is your program NAPRC Accredited?

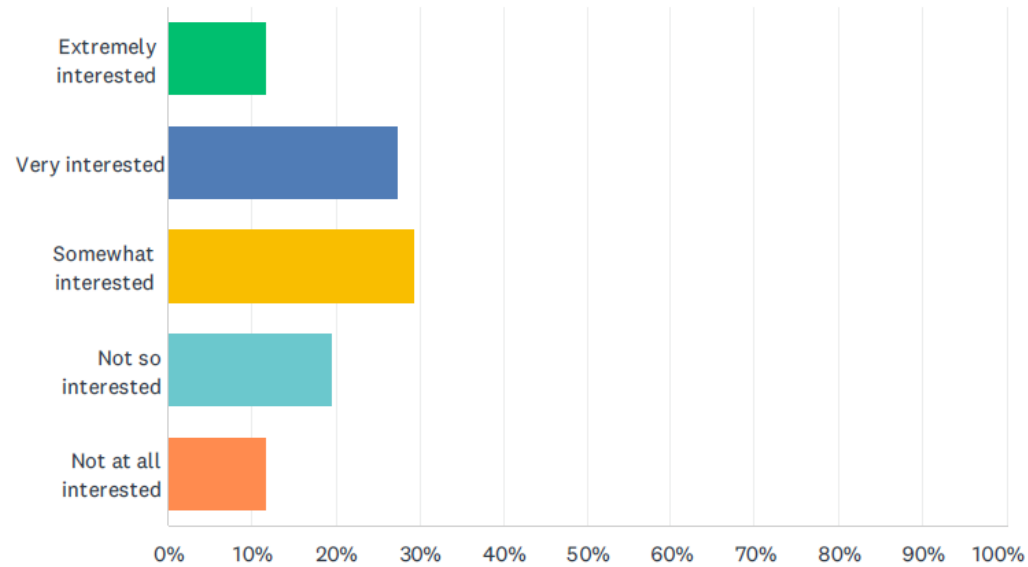
Answered: 52 Skipped: 0



ANSWER CHOICES	RESPONSES	
Yes	71.15%	37
No	0.00%	0
Applying for Accreditation	28.85%	15
<b>TOTAL</b>		<b>52</b>

# Are you willing to speak about your process during a webinar or at an in-person event?

Answered: 51 Skipped: 1



ANSWER CHOICES	RESPONSES	
Extremely interested	11.76%	6
Very interested	27.45%	14
Somewhat interested	29.41%	15
Not so interested	19.61%	10
Not at all interested	11.76%	6
<b>TOTAL</b>		<b>51</b>



National Accreditation Program for Rectal Cancer  
American College of Surgeons

# Virginia Mason Franciscan Health



[This Photo](#) by Unknown Author is licensed under [CC BY-NC](#)

# Standard 5.10 Photographs of Surgical Specimens: Challenges and Solutions with Implementing the Standard

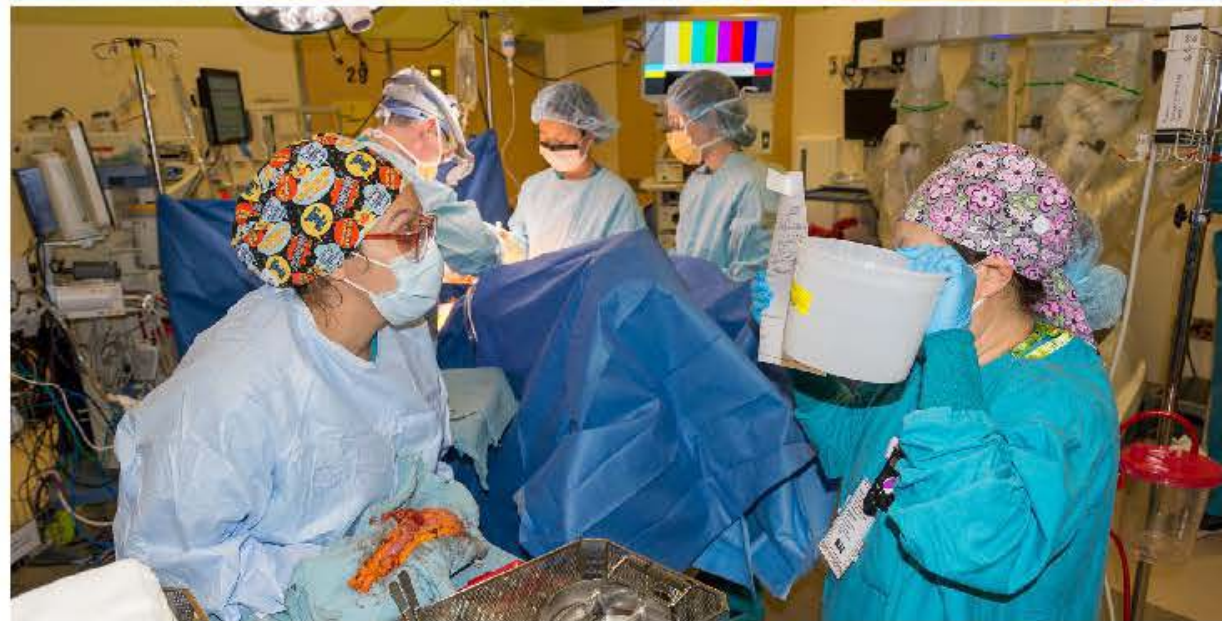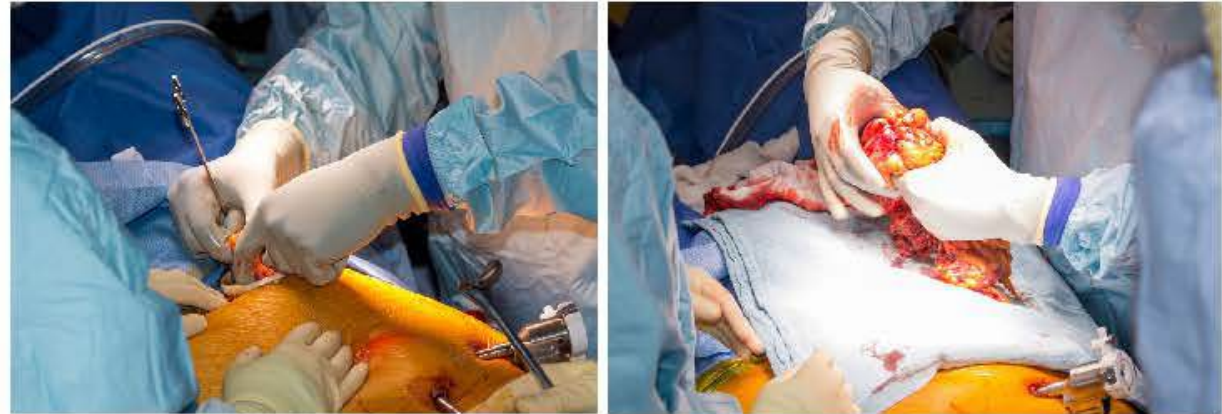April 18<sup>th</sup>, 2023



**National Accreditation Program for Rectal Cancer**  
American College of Surgeons

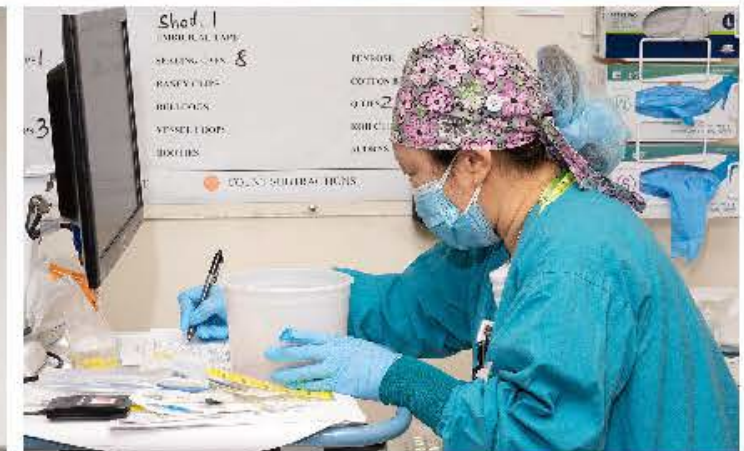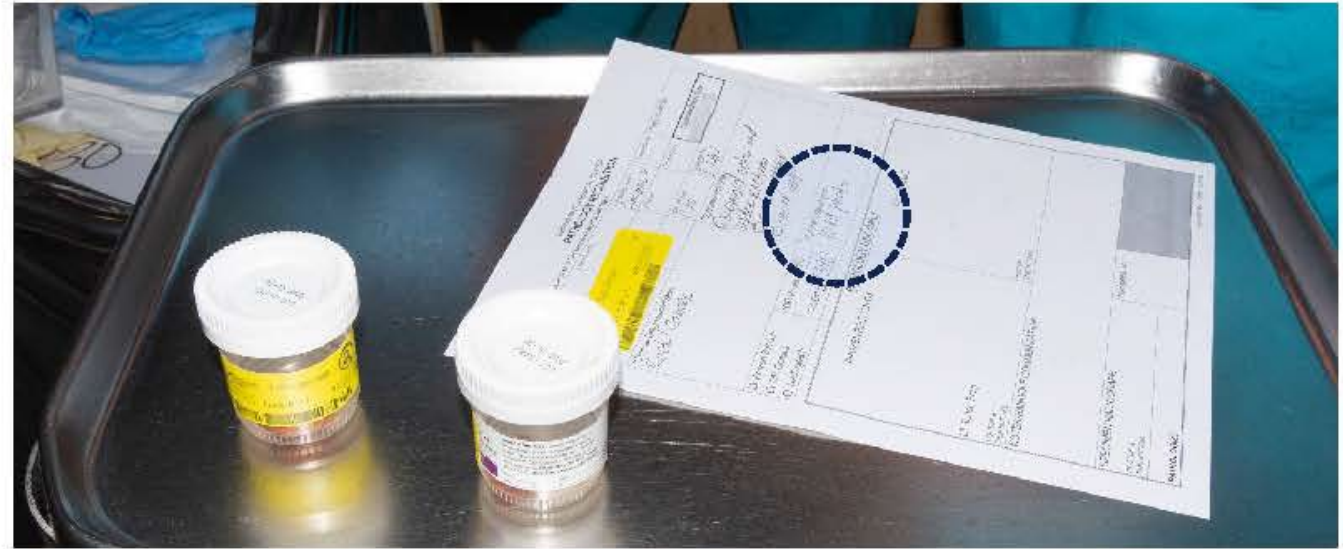
# Operating Room Procedure for Pathology

- Circulator / Surgeon confirm need for medical photograph
  - selectively → routinely for all colorectal cancer specimens
- Specimen sent fresh/unopened to pathology



# Operating Room Procedure for Pathology

- Circulator / Surgeon confirm need for medical photograph
  - selectively → routinely for all colorectal cancer specimens
- Specimen sent fresh/unopened to pathology



# Meanwhile, in Pathology...





# Medical Photographer Procedure

## VMMC Policy and Procedures (std X.Y)

- Photograph all rectal cancer specimens using Medical Photography services as follows and upload to PicsPlus:
  - Un-inked anterior, posterior, and lateral views prior to opening to demonstrate completeness of mesorectal envelope.
  - Open specimen demonstrating tumor and relevant structures/margins.
- Any requested colon resection indicated by surgeon for Medical Photography, employ Medical Photography services and upload to PicsPlus.
  - Un-inked intact and open views.
- All other colon specimen photos can be taken by the Surgical Pathology team and uploaded to PicsPlus for documentation.



### STD 5.10: Photographs of Surgical Specimens

Category: Organizational  
 Sub-Category: Accreditation Participation Other: Cancer Institute  
 Type: POLICY  
 Status: Approved  
 Last Reviewed: 10/22/2021  
 Regulatory Source(s): OTHER National Accreditation Program – Rectal Cancer  
 Regulatory Citation Number(s): Standard 5.10  
 Citation title: RCP\_ Photographs of Surgical Specimens

**PURPOSE:** This P&P outline the process for obtaining, displaying, and storing photographs of rectal cancer specimens

**SCOPE:** All Staff

#### **POLICY & GUIDELINES**

Photographs of the fresh or formalin fixed ex-vivo specimen may be obtained using any standard digital camera in either the operating room or in the pathology laboratory. These images are shown and discussed at Rectal Cancer Multidisciplinary Team (RC-MDT) meetings and are electronically stored with a patient identifier.

A minimum of 65% of all eligible surgical specimens **must be photographed:**

- Include four views: anterior, posterior, and two lateral views
- Presented to and discussed by the RC-MDT and electronically stored with the patient identifier.

If the specimen is photographed but not presented and discussed at an RC-MDT meeting, then it does not qualify for the 65% required for compliance with this standard.

#### **COLON AND RECTUM NEOPLASIA (88309)**

Specimen Processing Photography:

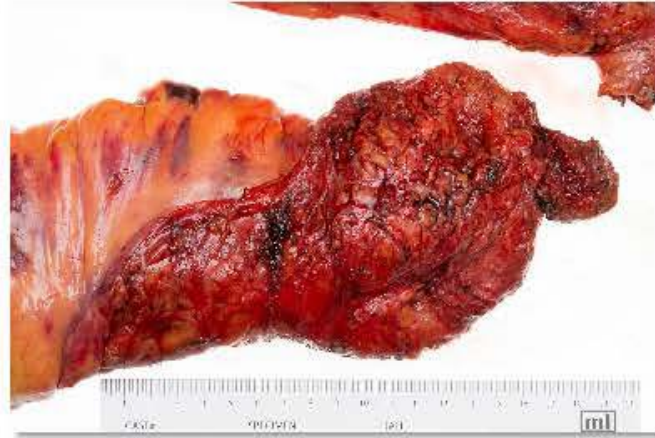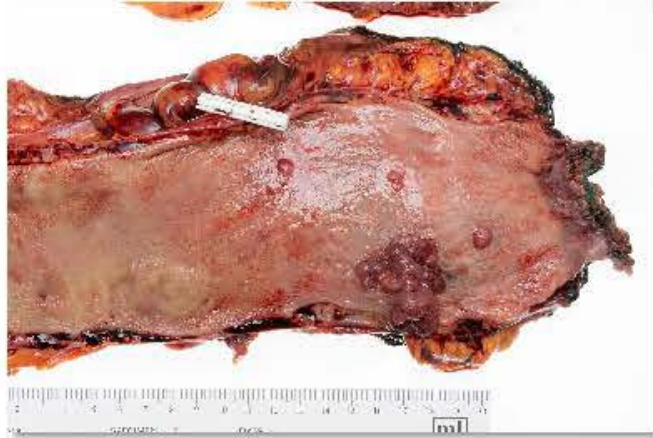
- Photograph all rectal cancer specimens using Medical Photography services as follows and upload to PicsPlus:
  - Un-inked anterior, posterior, and lateral views prior to opening to demonstrate completeness of mesorectal envelope.
  - Open specimen demonstrating tumor and relevant structures/margins.
- Any requested colon resection indicated by surgeon for Medical Photography, employ Medical Photography services and upload to PicsPlus.
  - Uninked intact and open views.
- All other colon specimen photos can be taken by the Surgical Pathology team and uploaded to PicsPlus for documentation.

Currently, photos are organized by operating surgeon and patient name and MRN, securely stored at \\vmfs-meddata\MedData\Clinical Photo\Clinicals

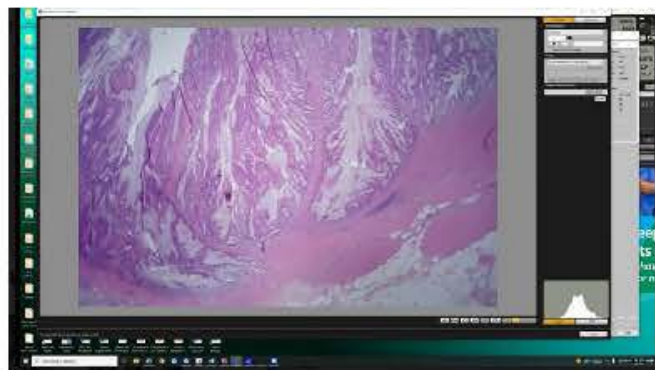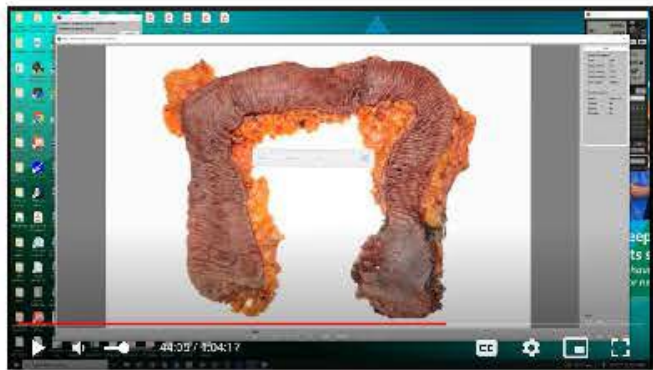
#### **Virginia Mason Internal Medical Record Review**

At a minimum, a random sample of 20 percent of eligible patient medical records or a maximum of 100 cases will be reviewed by the Rectal Cancer Program (RCP) Director each calendar year to evaluate compliance with this standard. The RCP Director may delegate this review to an appropriately

# Tumor Board Pathology Photos Presentation

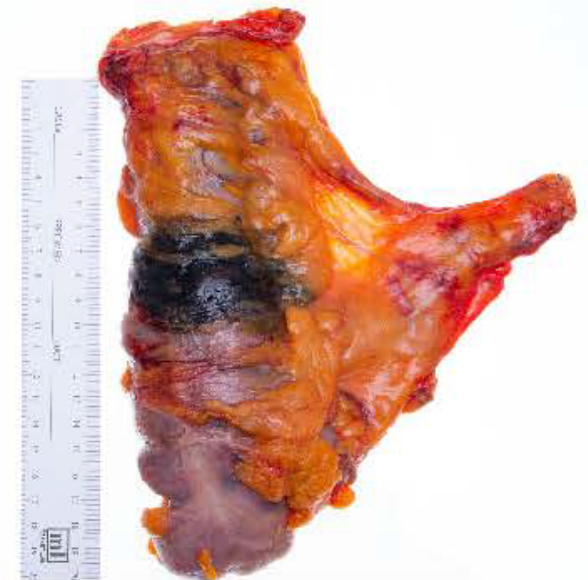
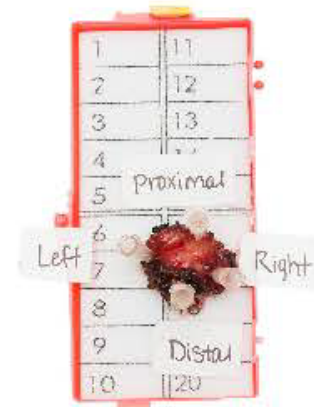
- Anterior, posterior, and two lateral views presented with the pathology during Post-Op Tumor Board presentation
  - Grade of the TME discussed
- Pathology discussion the proceeds as normal



# Protocol implications for other colorectal cancers

- Protocol has extended to all pathology for colorectal tumor board pathology reviews
  - Colon and Anal cases discussed and documented in the same way
- Challenges / Opportunities ahead
  - Cases that finish “after hours”
  - Standardizing path presentation of photos?
  - Photos sent to patients / referring providers



# Questions?



Mark Your Calendar for the 2024 ACS Cancer Conference

February 22 – 24

Austin, Texas

