

A Complex Surgical Patient: Arterioenteric Fistula Secondary to Coil Embolization

AUTHORS:

Abhishek Jairam^a; Alicia Gingrich, MD^a; Catherine Vu, MD^a; Brian C. Beldowicz, MD^{a,b}

CORRESPONDENCE AUTHOR:

Abhishek Jairam
UC Davis School of Medicine
4610 X Street, Sacramento, CA 95817
Phone: (805) 796-7299
Email: akjairam92@gmail.com

AUTHOR AFFILIATIONS:

a. UC Davis School of Medicine
Departments of Surgery and Radiology
Sacramento, CA 95817
b. Uniformed Services University of the Health Sciences
Department of Military and Emergency Medicine
Bethesda, MD 20814

Background	The patient is an elderly woman who underwent a laparoscopic cholecystectomy complicated by common bile duct injury and right hepatic artery pseudoaneurysm (HAP). Coil embolization of the pseudoaneurysm resulted in the formation of an arterio-enteric fistula presenting as a life-threatening gastrointestinal hemorrhage. This case highlights a delayed and exceedingly rare complication to one of the most common operations performed in general surgery.
Summary	Our patient underwent a Roux-en-Y choledochojejunostomy for a common bile duct injury sustained during laparoscopic cholecystectomy. She developed a pseudoaneurysm of the right hepatic artery three weeks post-operatively and underwent endovascular coil embolization of the pseudoaneurysm. Her recovery was further complicated by erosion of the coils into the duodenum, resulting in a brisk upper gastrointestinal hemorrhage secondary to an arterio-enteric fistula. The hemorrhage was controlled with right hepatic artery embolization and after stabilization the diagnosis was confirmed endoscopically. This case provides a unique learning opportunity to educate surgeons on a rare complication of coil embolization in the context of a complex surgical patient.
Conclusion	The treatment of this patient's complications required a multidisciplinary team, including surgery, interventional radiology, and gastroenterology. To our knowledge, such a complication has not been reported in the literature. Coil embolization in extrahepatic arterial segments does have a risk for coil migration and so stenting or embolization should also be considered.
Keywords	Hepatic artery pseudoaneurysm, arterio-enteric fistula, coil migration, stenting, embolization, iatrogenic bile duct injury

DISCLOSURE:

The authors have no conflicts of interest to disclose.

To Cite: Jairam A, Gingrich A, Vu C, Beldowicz BC. A Complex Surgical Patient: Arterioenteric Fistula Secondary to Coil Embolization. *ACS Case Reviews in Surgery*. 2019;2(4):46-49.

Case Description

Common bile duct (CBD) injury is one of the most dreaded complications of laparoscopic cholecystectomy, often as a result of indiscernible or misunderstood anatomy. Such injuries therefore rarely occur in isolation. Right hepatic artery injury has been observed in 41–61 percent of cases of iatrogenic common bile duct injury.¹ Typically this injury is observed as arterial thrombosis, but pseudoaneurysm has also been observed in rare instances. We report a case of right hepatic arterio-enteric fistula resulting from erosion of endovascular coils following iatrogenic common bile duct injury and right hepatic artery pseudoaneurysm (HAP).

The patient is an elderly woman who was transferred to our facility after laparoscopic cholecystectomy for cholelithiasis complicated by CBD injury. The surgeons performed a Roux-en-Y choledocojejunostomy at the index operation, complicated post-operatively by a bile leak. Prior to transfer, three external drains were in place: one surgically placed closed suction drain posterior to the choledocojejunostomy, one transenteric retrograde catheter across the choledocojejunostomy and one percutaneous transhepatic pigtail catheter with its tip proximal to the choledocojejunostomy in the right hepatic duct. Upon arrival at our institution, the patient was afebrile and hemodynamically stable but required continuation of intravenous antibiotics, drain management and nutritional support. She was discharged five days later with scheduled outpatient follow-up to monitor drain output, trend hepatic function tests, and perform a cholangiogram.

Eight days later, she presented to the emergency department hypotensive with bright red blood per rectum. Initial work-up included nasogastric lavage, which was negative for an upper gastrointestinal source. A computed tomography (CT) of the abdomen demonstrated a 3.6 cm pseudoaneurysm of the right hepatic artery but no clear communication between this injury and the gastrointestinal tract (Figure 1).

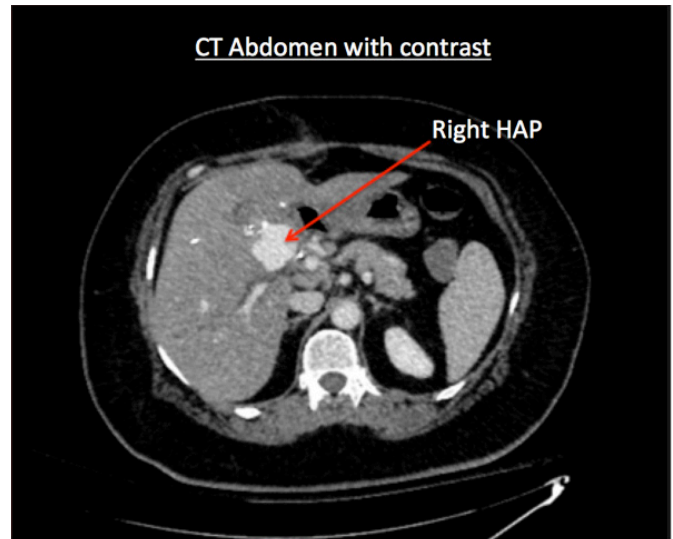


Figure 1. CT demonstrating evidence of right HAP.

She was admitted to the surgical intensive care unit for resuscitation and hemodynamic monitoring. Interventional radiology (IR) performed endovascular coil embolization of the pseudoaneurysm sac. A postprocedure CT angiography demonstrated stable coils and no evidence of persistent arterial hemorrhage. Esophagogastroduodenoscopy (EGD) was negative for bleeding source or fistula formation, but was positive for a nonspecific submucosal lesion at the duodenal bulb believed to be extrinsic compression from the adjacent hematoma. The patient's hemoglobin stabilized, she remained hemodynamically stable and was discharged on hospital day eight.

The patient returned the following night with right upper quadrant pain, bright red blood per rectum and hematemesis, and was again found to be hypotensive. A repeat CT angiogram demonstrated no IV contrast extravasation. She was admitted to the surgical intensive care unit (ICU). After responding to resuscitation and a period of stability, the patient acutely decompensated with large-volume hematemesis and hemodynamic instability requiring massive transfusion. Angiography demonstrated expansion of the previously embolized pseudoaneurysm with new active extravasation from the right hepatic artery (Figure 2).

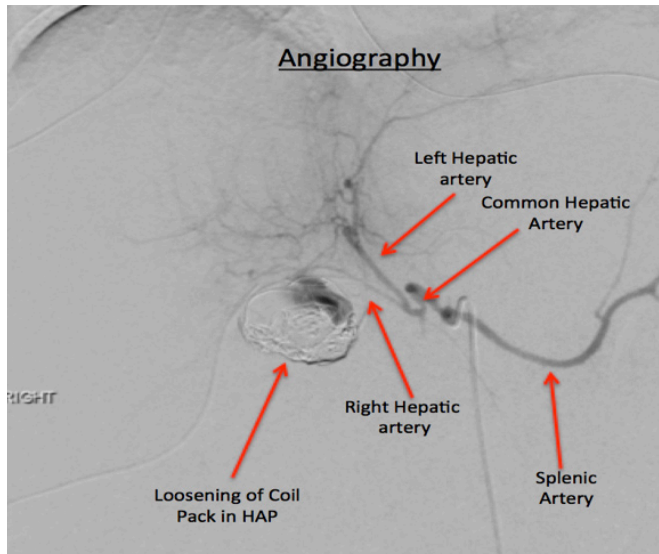


Figure 2. Angiography demonstrating evidence of coil pack loosening and contrast extravasation from the right hepatic artery into the pseudoaneurysm.

Additionally, intravenous contrast was seen collecting within the small bowel, and a small collection of extra-intestinal, paraduodenal air raised concern the coils had eroded into the duodenal lumen creating an arterio-enteric fistula. As resuscitation continued, the proximal right hepatic artery was embolized distal and proximal to the site of extravasation, and the patient stabilized.

An EGD with push enteroscopy performed the following day confirmed the erosion of coils into the second and third portions of the duodenum (Figure 3).

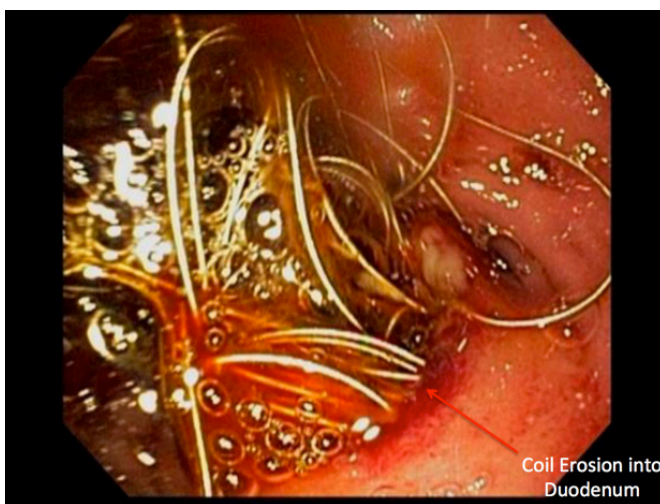

Figure 3. EGD depicting the presence of coils in the duodenum.

Attempts to retrieve the coils endoscopically were unsuccessful given their small, mobile nature. Direct visualization of the bowel lumen confirmed absence of obstruction. Examination of the jejunojunal anastomosis and the Roux limb were normal. Patient was maintained on total parenteral nutrition until an upper gastrointestinal contrast study on post-procedure day seven demonstrated no leak. She was then started on low-volume enteral feedings, which were advanced to her goal rate without complication. The coils were not visualized on further imaging and no additional endoscopy was performed. Patient continues to have routine follow-up with the surgery clinic, has had the drains removed, and is currently in stable condition one year later.

Discussion

This case demonstrates an uncommon series of complications secondary to initial CBD injury during an elective cholecystectomy. HAP secondary to iatrogenic injury continues to be exceedingly rare with only five reported cases in the last 24 years.² Endovascular therapies have evolved into the first line treatment for the management visceral pseudoaneurysms. Compared to open surgery, there is reduced morbidity and mortality with similar survival rates long term.³ However, there are limited reports illustrating patient complications post-coil embolization of visceral vasculature. Current literature suggests they are rare, but may include delayed hemorrhage, infarction, necrosis, abscess formation, bilioma or biliary fistula.⁴

Multiple embolization strategies for treating visceral artery pseudoaneurysms exist that derive from a concept of occluding blood flow into the sac to prevent expansion and rupture. Available methods include coiling of the sac, deployment of covered stent grafts across the sac, coiling through a bare stent, liquid embolic agents, and thrombin injections for more superficially located target sites.³ In the setting of HAP, the injury is more common in the extra-hepatic segment of the proximal hepatic artery, and endovascular stent-grafting should be considered as first line therapy.⁵⁻⁶ Covered stent grafts are of benefit as they are designed to inhibit sac inflow while maintaining parent vessel patency. However, vessel size, tortuosity and inadequate landing zones may preclude stent-grafting. Coiling of the pseudoaneurysm sac was the chosen intervention for this patient. When packed into a pseudoaneurysm, coils occlude arterial inflow and induce inflammation

and thrombosis through their thrombogenic fibers.⁷ Coiling is indicated for pseudoaneurysms with short necks as those with wide necks have an increased risk for non-target embolization. Parent artery embolization is another option, however there is a risk of end-organ ischemia in the absence of collateral perfusion.⁷

Prior to any intervention, patients require imaging assessment with computed tomography angiogram (CTA) or magnetic resonance angiogram (MRA) to better understand vascular anatomy. Postoperatively, patients require a repeat angiogram or Duplex ultrasound to ensure successful occlusion with lack of pseudoaneurysm inflow. Post-embolization syndrome may develop one to three days following intervention and will present as fever, nausea, and malaise with leukocytosis. The management of this syndrome is focused on alleviation of symptoms with antipyretics, antiemetics, and analgesics. Other complications include non-target embolization, abscess formation, and end-organ ischemia. Ultimately, patients should have routine follow-up in interventional radiology outpatient clinic with CTA or MRA at one month, six months, and then yearly to assess pseudoaneurysm sac size and adequate end organ perfusion.

As innovations continue to drive endovascular interventions, it is important to share experiences of rare complications for the purposes of optimizing clinical skill, safety, and the quality of care delivered to patients. This case provides a unique learning opportunity to highlight a rare complication of coil embolization in the context of a complex surgical patient who underwent the most common procedure performed by general surgeons. In this particular patient, her vascular anatomy was not suitable for stent grafting. The erosion of the coils into the small bowel may have been from either coil pack expansion or exacerbation of what was originally an unknown mycotic pseudoaneurysm. Proximal and distal embolization may have avoided this complication and is ultimately what was required. Endovascular interventions have promising outcomes and reduced morbidity for cases such as this one. However, it is imperative surgeons are aware of the types of interventions available, the indications for each and the potential complications following such procedures.

Conclusion

This case provides insight into technical considerations when coiling visceral pseudoaneurysms, as well as diagnosing and managing a novel complication, an arterio-enteric fistula secondary to coil erosion into the proximal small bowel. The treatment of this patient's complications required multiple procedures from a multidisciplinary team, including surgery, interventional radiology, and gastroenterology. To our knowledge, such a complication has not been reported in the literature. We hope sharing this experience has the potential to improve the quality of care provided to our patients.

Lessons Learned

Endovascular stent-grafting should be considered first line in extrahepatic arterial pseudoaneurysms. Pseudoaneurysm sac embolization in such cases has a risk for coil erosion and migration.

References

1. Raashed S, Chandrasegaram MD, Alsaleh K, et al. Vascular coil erosion into hepaticojejunostomy following hepatic arterial embolisation. *BMC Surg*. 2015;(15):51.
2. Pulitanó C, Parks RW, Ireland H, et al. Impact of concomitant arterial injury on the outcome of laparoscopic bile duct injury. *Am J Surg* 2011;201(2):238–244.
3. Saad NE, Saad WE, Davies MG, et al. Pseudoaneurysms and the role of minimally invasive techniques in their management. *Radiographics*. 2005;25:73–89
4. Moukaddam H, Al-Kutoubi A. Pseudoaneurysms of hepatic artery branches: treatment with self-expanding stent-grafts in two cases. *J Vasc Interv Radiol*. 2007;18(7):897–901.
5. Laganà D, Carrafiello G, Mangini M, et al. Multimodal approach to endovascular treatment of visceral artery aneurysms and pseudoaneurysms. *Eur J Radiol*. 2006;59(1):104–11.
6. Berceli SA. Hepatic and splenic artery aneurysms. *Semin Vasc Surg*. 2005;18(4):196–201.
7. Madhusudhan KS, Venkatesh HA, Gamanagatt S, et al. Interventional radiology in the management of visceral artery pseudoaneurysms: a review of techniques and embolic materials. *Korean J Radiol*. 2016;17(3):351–363.